Beating Heart Mitral Valve Surgery Challenging Case

K. Fon Huang, MD

Annual Scientific Meeting of The Missouri Perfusion Society
Hammons Heart Institute, Mercy Hospital, Springfield , MO
22nd June 2-3, 2017

- *Cardioplegia is a complex topic*
- *There is no perfect Cardioplegia solution or perfect technique.*
- *Can we simplify myocardial protection and still keep it safe and effective?*
- *Is it possible to never stop perfusing the heart and still have adequate visibility and exposure to perform complex heart valve surgery?*

Beating Heart Surgery Advantages

- During fibrillation, O2 delivery to the LV is reduced and coronary flow is redistributed away from the subendocardium. Deeper hypothermia not needed to compensate for subendocardial hypoperfusion.
- Warmer core temps decreases hypothermia –mediated coagulopathy. Fibrinolysis is decreased in patients on CPB @ 32'C.
- Beating Heart and Warmer temps eliminates the additional time for cooling and rewarming for V-fib arrest.

Beating Heart AV Valve Surgery Guiding Principles

- No or minimal CAD
- Complete decompression/ drainage and unloading of the heart. NO EJECTION. Flat A-line, Echo shows no Ao valve opening.
- CO_2 flooding of the field.
- In MV surgery, mild or no AI preferred.
- Keep the Aortic root filled , Aortic valve closed to prevent air / particle emboli.

Advantages of R thoracotomy for reop AV valve surgery

- Minimize dissection of mediastinum, aorta and heart – less surface oozing.
- Minimize risk of injury to great vessels, heart and prior bypass grafts.
- Little to no bleeding from sternotomy or bone surfaces.
- Optimal exposure with minimal distraction or distortion of the heart.

Mitral Valve Repair versus Replacement for Severe Ischemic Mitral Regurgitation

Michael A. Acker, MD, et al. N Engl J Med 2014; 370: 23 -32

- First randomized multi-center study of MV surgery on 251 patients undergoing either MV repair or chordal sparing MVR. 22 centers in the CTSN.
- Mortality at 1 year for MV repair = 14.3% vs MVR =17.6% (NS)
- No difference in LV remodeling
- No significant differences in composite of major cardiac or cerebrovascular events.
- No significant differences in QOL or Functional status at 1 year.
- ***BUT, the recurrence of mod-severe MR was 32% in Repair vs 2.3% in the MVR group!***
-

ECMO Salvage and Warm Beating Heart MVR in a Reop Patient with Cardiomyopathy and Flail Anterior Leaflet

- A short obese (62”, 208 lbs, BMI=38.3) diabetic 71 year old woman with prior CABG presents with hypotension, hyperglycemia, metabolic acidosis, nausea and abdominal pain. Admission Troponin was mildly positive.

Clinical presentation

- In 2005, she had a beating heart CABGX5 and TV repair (30mm MC3 ring). LVEF was 20 – 30 % and did not improve postop.
- Six months prior, Echo showed LVEF ~ 20%, Calcified Aortic stenosis; AVA =0.9 cm2, peak/mean gradient = 30/ 19 mm Hg and mild to moderate MR.
- Current Echo shows flail anterior MV leaflet, severe eccentric MR and no change in the aortic valve.

Echo

Intact TV Repair

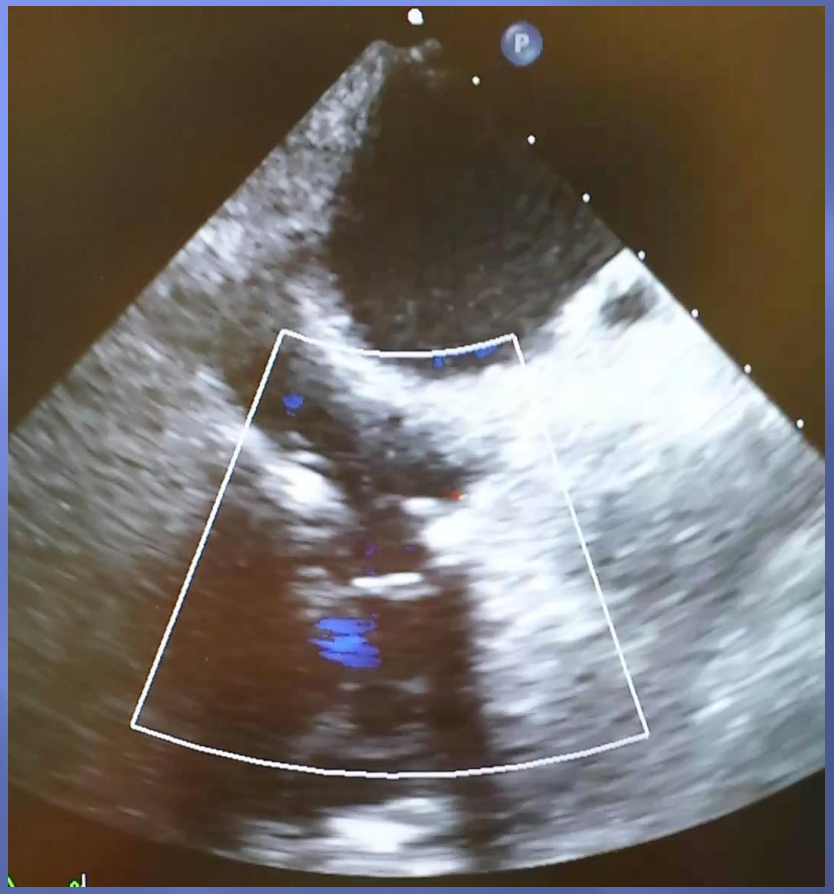

Aortic stenosis, flail Anterior MV

Echo : flail anterior MV leafelt

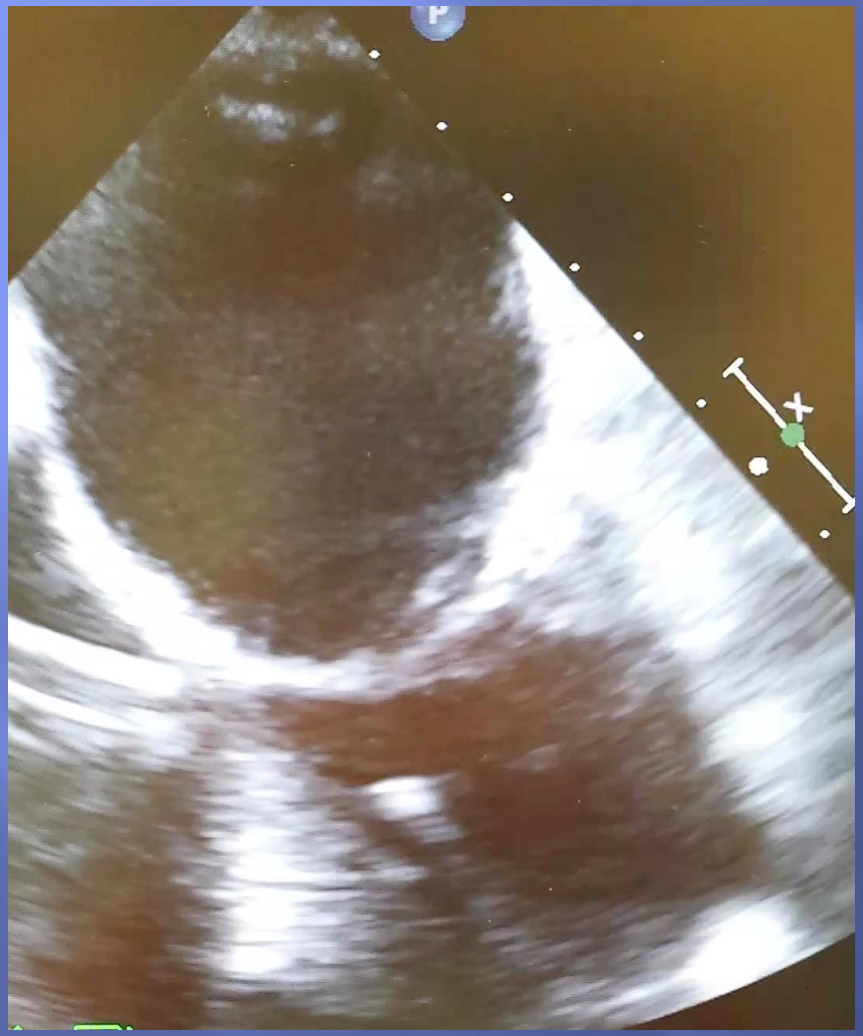

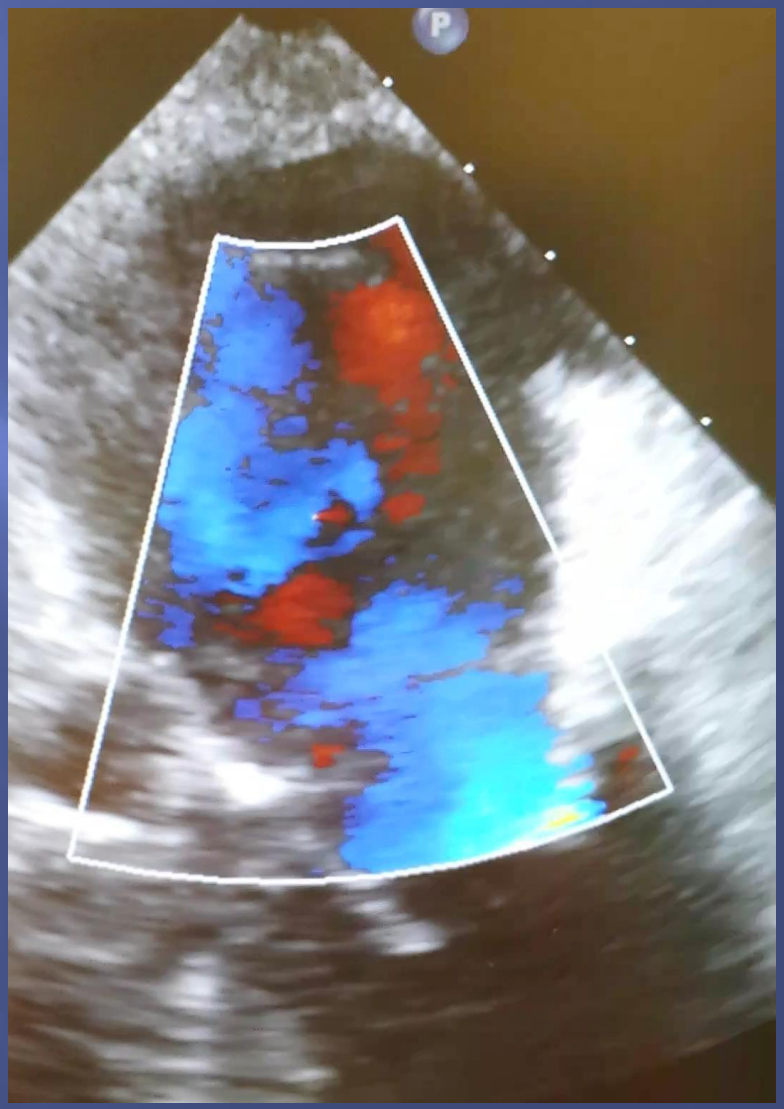

3D Echo

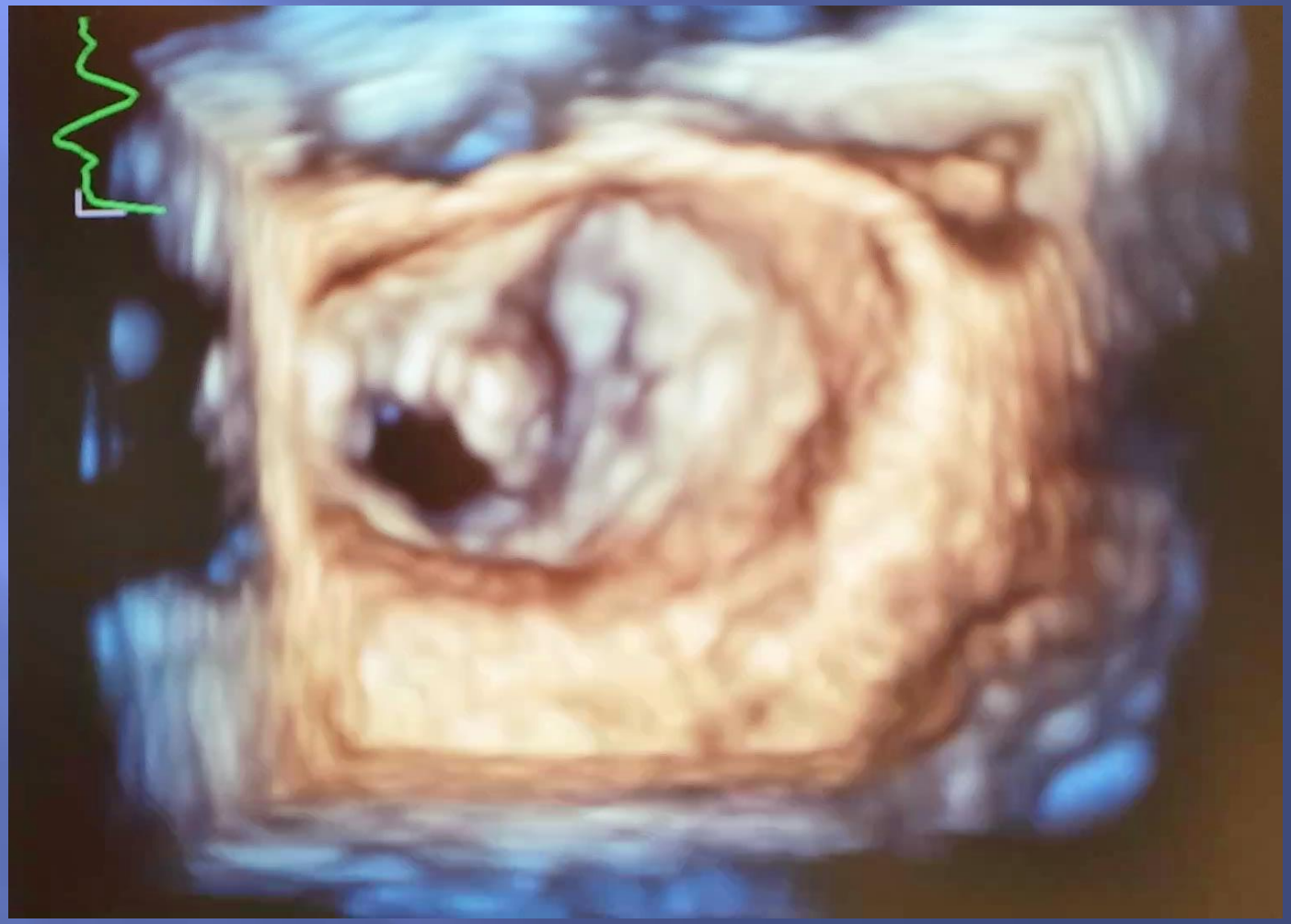

Cath coronaries

Nondominant RCA

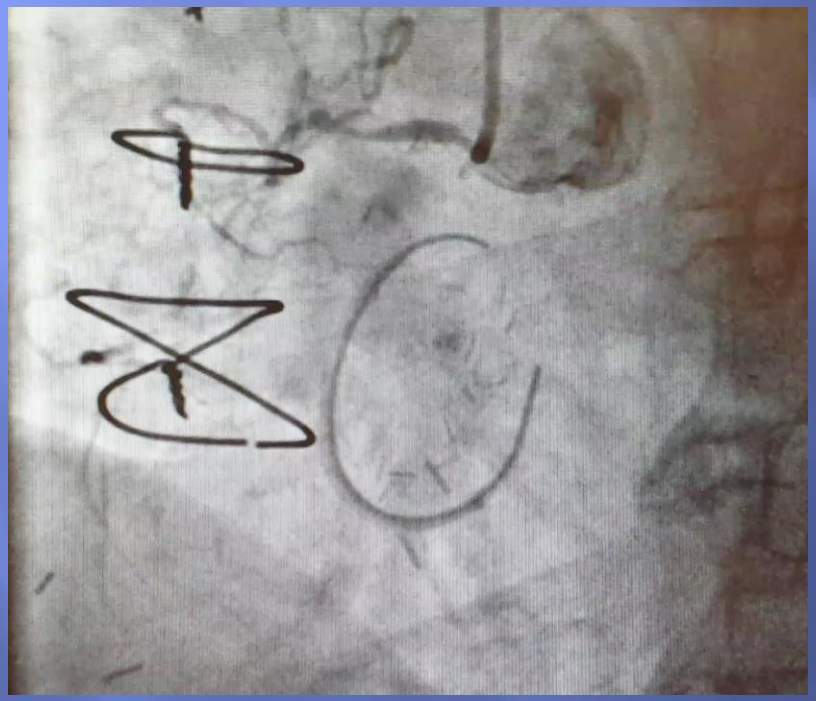

Left Main

Cath: grafts

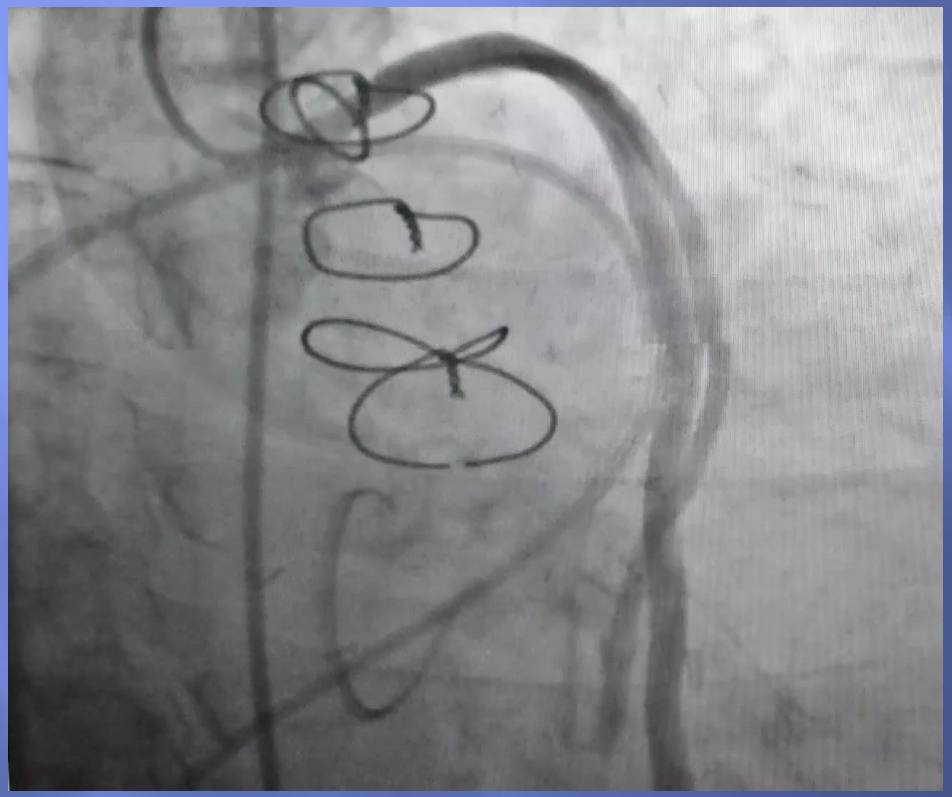

Sequential PDA + PLVB graft

Cath grafts

Sequential LIMA – Diag + LAD

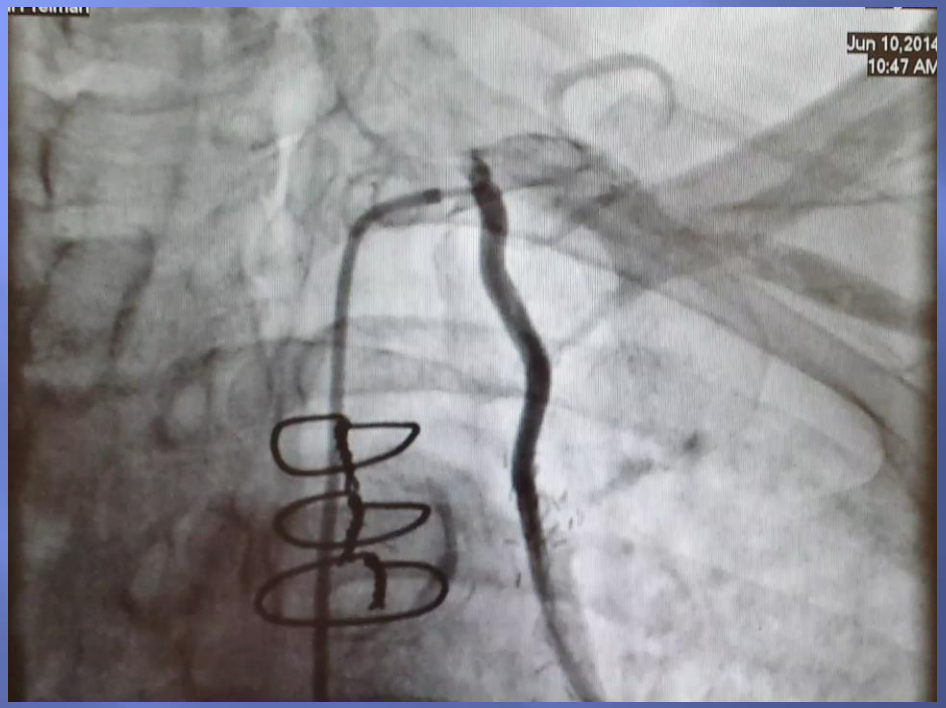

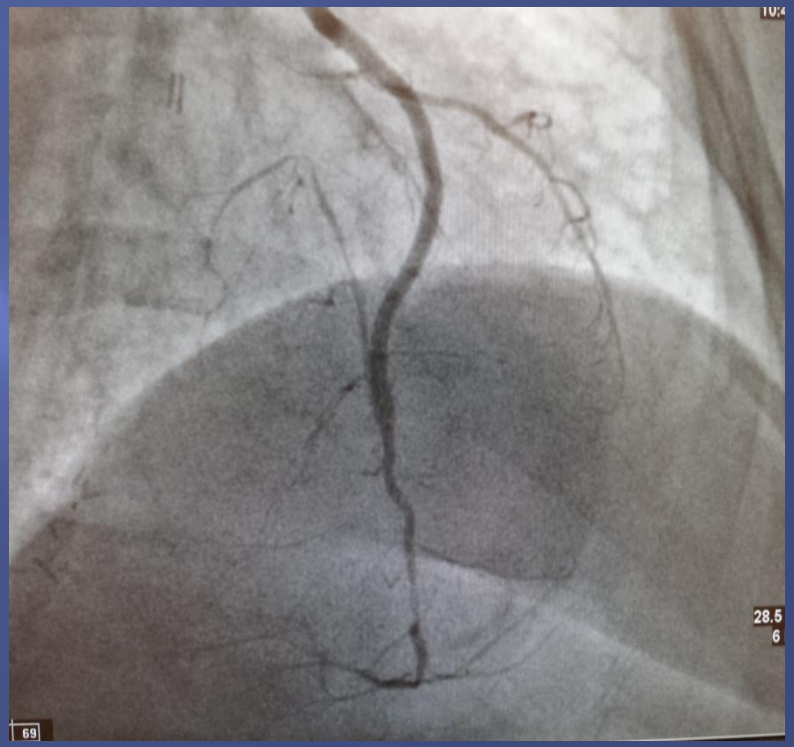

LV grams 6 months prior & now

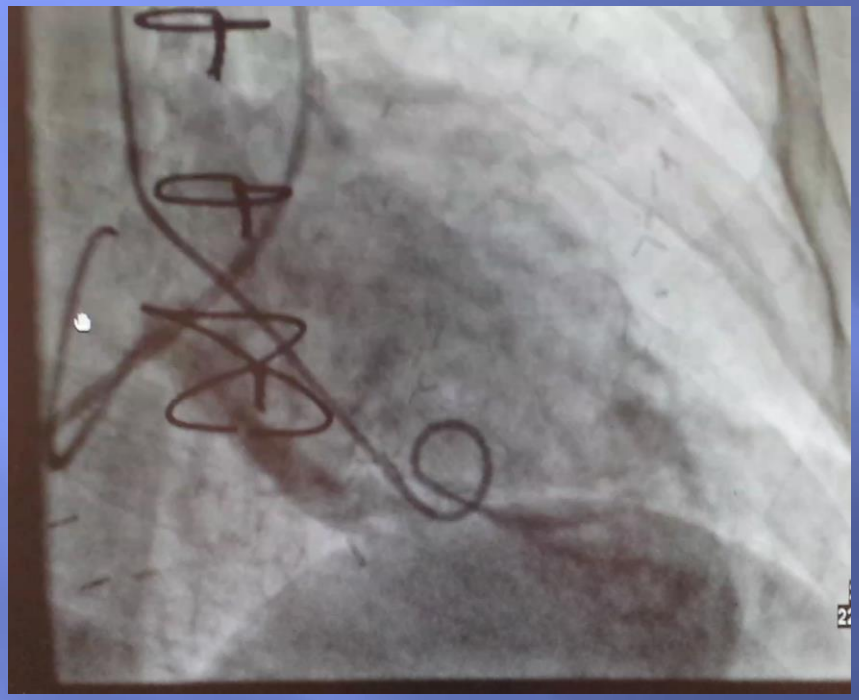

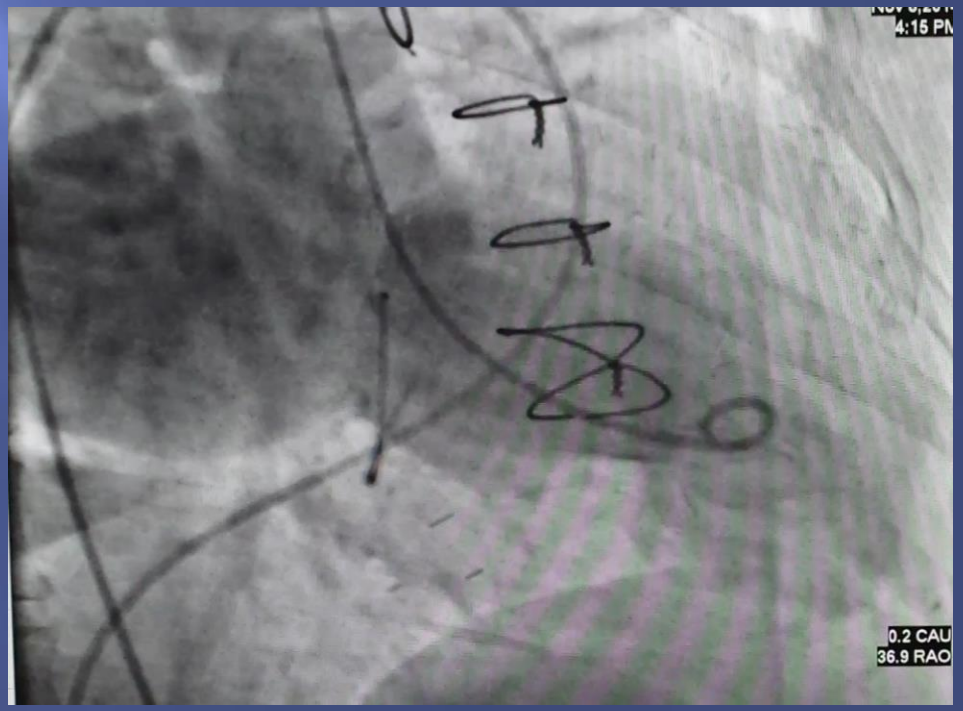

RV pressure = 73/21, pcwp = 29. BP = 87/64.

Preop Course

- She was intubated for progressive respiratory failure, femoral IABP was placed in cath lab.
- CV Surgery is consulted.
- Overnight she develops shock liver, ALT 2906, AST 4464 and oliguric renal failure, creatinine 1.1 to 2.3.
- What to do next?

Possible options

- Emergency surgery?

STS Op Mortality risk: Emergent MVR= 75%

- Approach: redo sternotomy vs thoracotomy?
- AVR + MV Repair or Replacement
- MV Repair or Replacement alone
- Hemodynamic support: VAD vs ECMO followed by staged surgical Rx.
- Medical/ Palliative Care?

Surgical Action Plan

- Discussion among surgical partners (Friday night) : Redo sternotomy approach for combined AVR, MVR was thought to be not survivable in this situation.
- Taken to OR, IABP was removed and Veno-arterial ECMO established by Right Femoral cutdown using 17Fr Medtronic DLP arterial and 25Fr multistage venous cannula.
- Over the next 24 to 30 hours, her liver and renal function improved dramatically.

Operative Strategy

- Operative strategy is to address her acute CHF from MR with a minimally invasive thoracotomy approach on a beating heart which would also minimize global ischemic time.
- All anterolateral chords to the anterior leaflet were ruptured.
- ECMO cannulas were used for CPB. Total CPB time = 169 min with no aortic cross clamp.
- 29mm porcine MVR done with complete posterior leaflet and anterior/ commissural chords preserved. Intraop she received 2 units of blood and one platelets. She was switched back to ECMO support for postop recovery.

Post MVR

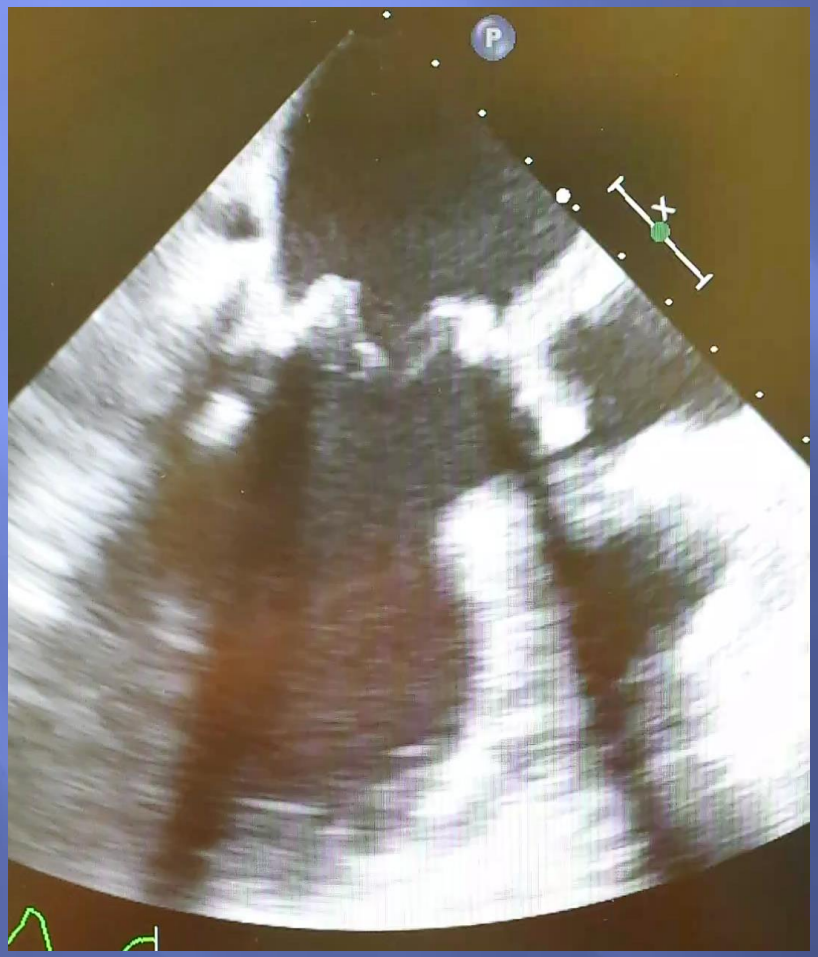

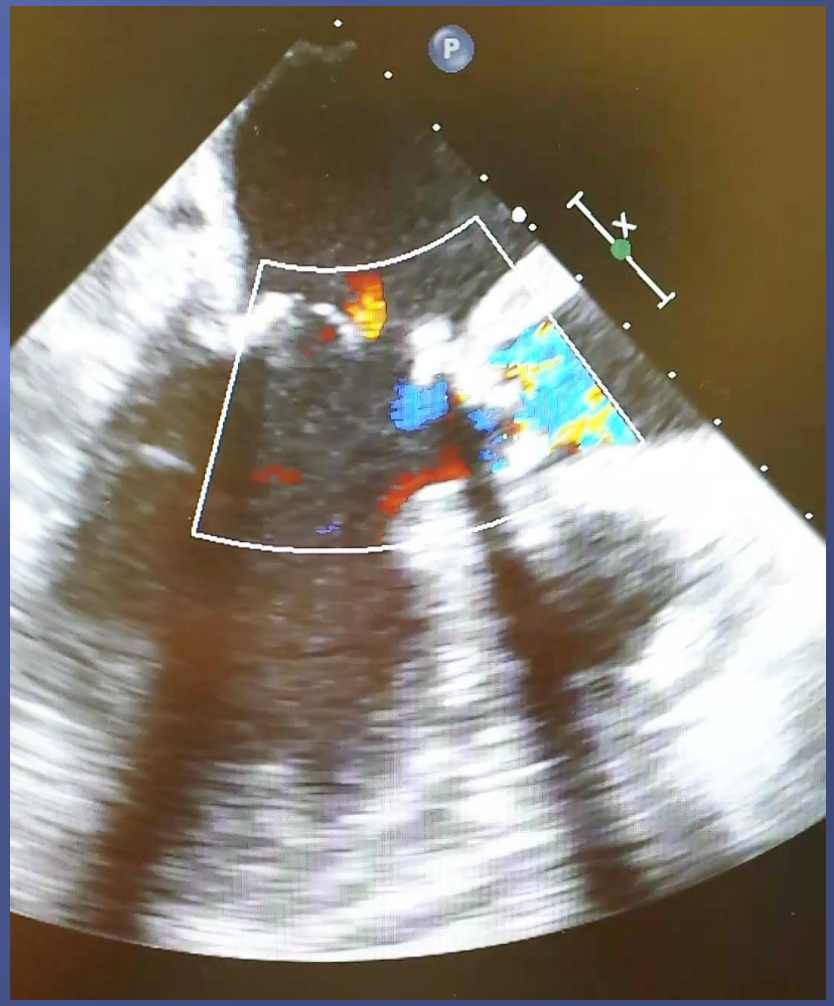

Postop course of Recovery

- The following day, she was weaned from ECMO, taken back to the OR for decannulation and placement of a left femoral IABP.
- IABP support was removed 4 days postop. She was extubated 6 days postop and transferred out of ICU 2 days later. Patient was discharged with Home Health Care 11 days postop.
- At one month followup, she was doing well, using a walker and able to perform independent activities of daily living.

Conclusion

- A strategy of preop ECMO resuscitation and then a beating heart MVR can successfully salvage a complex reoperative cardiomyopathy patient suffering from cardiogenic shock and multiorgan failure from acute severe MR.